

# Salvage of Congested Deep Inferior Epigastric Perforator Flap With a Reverse Flow Venous Anastomosis

Tom S. Liu, MD, MBA, Peter Ashjian, MD, and Jaco Festekjian, MD

**Abstract:** The deep inferior epigastric perforator flap (DIEP) is an increasingly popular method for autologous breast reconstruction because of less abdominal wall donor-site morbidity. However, disadvantages with the DIEP flap are its greater technical difficulties for flap harvest and a greater incidence of venous congestion. We report a case of salvage of a congested DIEP flap with a superficial inferior epigastric vein (SIEV) to deep inferior epigastric vein reverse flow anastomosis. Drainage of both the superficial and deep system resulted in complete reversal of venous congestion and flap salvage. Preservation and use of the SIEV for venous augmentation via a reverse flow anastomosis is a novel and simple method for DIEP flap salvage of venous congestion.

**Key Words:** DIEP flap venous congestion, venous augmentation, flap salvage

(*Ann Plast Surg* 2007;59: 214–217)

Since its description in 1989, the deep inferior epigastric perforator (DIEP) flap has become increasingly popular for autologous breast reconstruction.<sup>1,2</sup> Despite continued controversy related to its purported advantages, it provides a reliable and safe technique in properly selected patients. By minimizing musculofascial sacrifice, it has been shown to have less postoperative pain, reduced hospital stay, increased abdominal strength, and faster recovery.<sup>3–5</sup> However, disadvantages of the DIEP flap include more tedious flap dissection, additional clinical acumen for perforator selection, increased venous congestion, and fat necrosis.<sup>6,7</sup> Incidence of venous congestion in DIEP flaps has been shown to range from 3%–6%.<sup>2,7,8</sup> Various techniques have been shown to provide venous augmentation of a congested DIEP flap.<sup>9,10</sup> These cases require an additional venous anastomosis for decongestion and salvage. Often these conduits require difficult flap dissection and occasionally vein grafts. The additional time needed for these maneuvers places the already congested flap at additional risk.

Received August 30, 2006, and accepted for publication September 25, 2006. From the UCLA Medical Center, Department of Surgery, Division of Plastic and Reconstructive Surgery, Los Angeles, CA.

Reprints: Jaco Festekjian, MD, UCLA Medical Center, Department of Surgery, Division of Plastic and Reconstructive Surgery, 200 UCLA Medical Plaza, Suite 465, Los Angeles, CA 90095. E-mail: jfestekjian@mednet.ucla.edu.

Copyright © 2007 by Lippincott Williams & Wilkins

ISSN: 0148-7043/07/5902-0214

DOI: 10.1097/01.sap.0000250853.40099.49

We report a simple method of venous augmentation using an end-to-end anastomosis of the ipsilateral superficial inferior epigastric vein (SIEV) to the distal end of one of the vena comitantes of the DIEP pedicle (DIEV). The additional reverse venous flow of the SIEV-DIEV anastomosis provides augmented drainage of both the superficial and deep systems into a common deep system venous outflow. This resulted in immediate clinical decongestion of the flap. The technique is relatively simple and requires minimal added vessel dissection.

## Surgical Technique

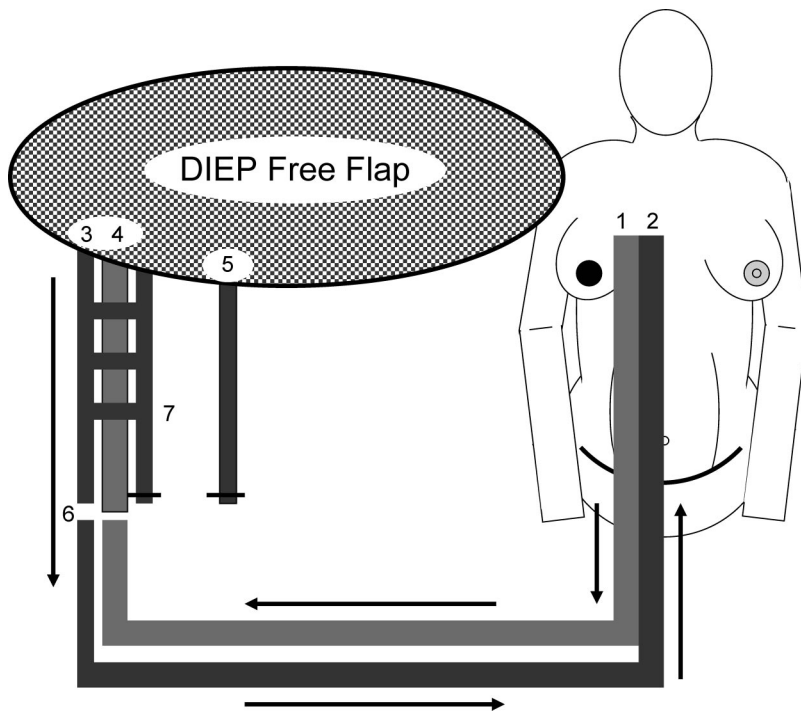
Routine preoperative evaluation of patients is performed based on medical comorbidities (diabetes, hypertension, smoking, obesity), oncologic history (delay versus immediate reconstruction, chemotherapy, radiation), and physical examination (prior abdominal scars, subcutaneous fat deposit, breast size versus abdominal girth). Patients deemed medically fit for surgery and without abdominal scar contraindications for free flap are scheduled for elective surgery. Patients are considered for DIEP flaps with the final determination to be made in the operating room based on perforator number, location, and caliber. If the patient is not a candidate for DIEP, a muscle-sparing free TRAM (MS-TRAM) is attempted first with a traditional free TRAM as a final choice.

Skin markings are made the day of surgery, and intraoperative Doppler examination is performed to identify location of the DIEPs and the superficial inferior epigastric vessels. Abdominal flap elevation is performed in the standard fashion, taking care to preserve both superficial inferior epigastric vascular pedicles.

## CASE REPORT

The patient was a 42-year-old female status post a right modified radical mastectomy in 1998 for invasive ductal carcinoma. The patient was treated with postoperative chemotherapy for 6 months and was not treated with breast radiation. She presented for evaluation for autologous breast reconstruction 8 years after her initial diagnosis of cancer and has remained cancer-free. She has no other medical problems and her only prior surgery, other than her mastectomy, was a C-section with a low abdominal Pfannenstiel incision. The patient does not smoke. She weighs 56 kg and is 165 cm tall.

At the beginning of flap harvest, both SIEV were identified and preserved. The ipsilateral SIEV was the larger of the 2, with an estimated 2.5-mm vessel caliber. Three lateral-row perforators were found to be acceptable for a DIEP flap, with a palpable pulse at each perforator. Medial



**FIGURE 1.** Congested DIEP flap after initial arterial-venous anastomosis. Arrows indicate direction of blood flow. 1, Internal mammary artery (IMA); 2, internal mammary vein (IMV); 3, deep inferior epigastric vein (primary vena comitante); 4, deep inferior epigastric artery (DIEA); 5, superficial inferior epigastric vein (SIEV); 6, DIEP-IM arterial and venous anastomosis; 7, DIEP vena comitante (H-shunt) intercommunications.

row perforators were occluded with vascular clamps to assess flap viability based solely on the 3 lateral-row perforators. The flap was noted to be pink and with good cap refill (1–2 seconds). There was no evidence of flap pallor or congestion. Skin edges were bleeding and Doppler signals were present.

The deep inferior epigastric donor vessels were ligated at their origin from the external iliac vessels. During DIEP harvest, the internal mammary recipient vessels were prepared by a second team. Donor and recipient vessel dimensions were deep inferior epigastric vessels (2.5-mm artery, 3.0-mm vein) (DIEA/DIEV) and internal mammary vessels (2.3-mm artery, 3.0-mm vein) (IMA/V).

Microsurgical anastomoses were performed between the DIEA and IMA and one of the vena comitantes and IMV with interrupted 9-0 nylon sutures. Fifteen minutes after revascularization, the flap appeared congested. The flap was blue, with brisk capillary refill of <1 second. Both the arterial and venous anastomoses were evaluated and were patent. The ipsilateral SIEV was unclamped to reveal dark venous bleeding. An end-to-end anastomosis between the SIEV and the unused DIEV pedicle was performed in a reverse venous flow fashion (see Figs. 1 and 2).

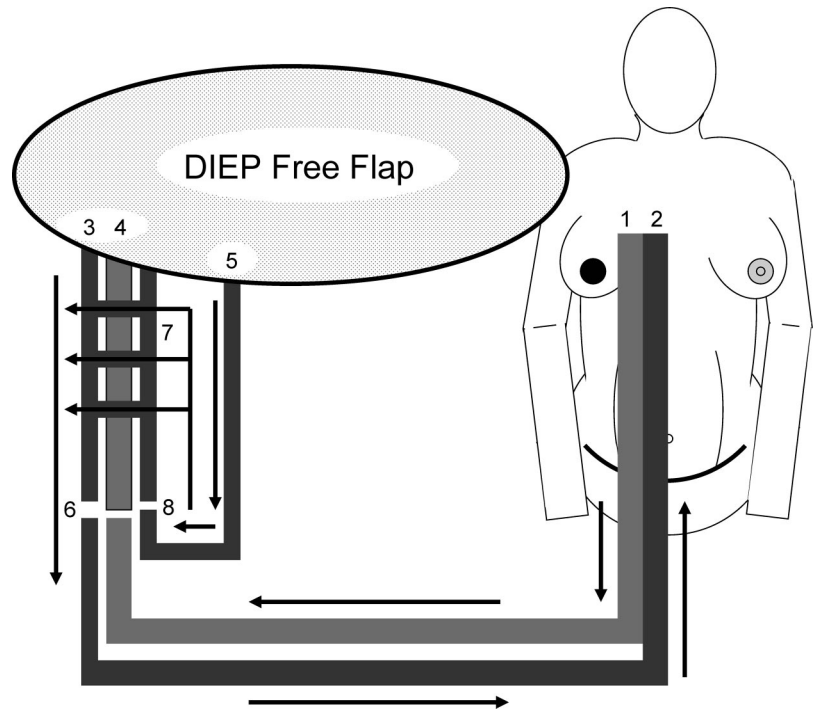
Prior to anastomosis, the vena comitantes pedicle was irrigated to ensure patency of reverse flow and absence of potential obstructing valves. There appeared several “H” connections between the vena comitantes upstream (toward the flap) from the second venous anastomosis. Ten minutes after venous supercharging, the flap appeared pink, with normal cap refill (1–2 seconds). Doppler signals were present on the cutaneous markings. The patient had an uneventful postoperative course, without venous congestion, loss of Doppler signal, or flap loss. The patient did not receive any periop-

erative or postoperative pharmacologic anticoagulation. The patient was discharged home on postoperative day 5.

## DISCUSSION

The free TRAM flap is the gold standard for autologous breast reconstruction. Problems with donor-site morbidity and postoperative pain have resulted in the evolution of more minimally invasive harvesting techniques, requiring reduced muscle (MS-TRAM), no muscle (DIEP), or even the complete absence of abdominal wall dissection (SIEA). Venous congestion remains a significant problem in the perioperative and postoperative period, which can threaten flap viability. Although venous congestion can occur with any type of flap, there appears to be a greater incidence reported for DIEP compared with free TRAM flaps. Blondeel et al<sup>7</sup> reported a series of 240 DIEP and 271 TRAM free flaps across 2 institutions and over 10 years. Four cases of venous congestion were detected in the DIEP group and none in the TRAM group.

Multiple successful methods of venous augmentation, salvage, and supercharging have been reported to overcome the problem of venous congestion in DIEP flaps. Cohn and Walton<sup>11</sup> anastomosed the DIEV and SIEV to 2 separate recipient vessels, the internal mammary and thoracodorsal vessels. Niranjana et al<sup>12</sup> reported success of venous augmentation of the opposite DIEV to the cephalic vein using an interposition vein graft. Tutor et al<sup>13</sup> described venous augmentation with a vena comitantes to an intercostal branch of the IMV. Although any one of these techniques can result in successful venous augmentation and flap salvage, they are limited by dissection of a second recipient vein and occasional nonoptimal geometry. These factors contribute to added time and morbidity.



**FIGURE 2.** Salvage of DIEP flap venous congestion after reverse flow venous anastomosis. Arrows indicate direction of blood flow. 1, IMA; 2, IMV; 3, DIEV; 4, DIEA; 5, SIEV; 6, DIEP-IMA arterial and venous anastomosis; 7, DIEP vena comitante (H-shunt) intercommunications with reverse venous blood flow; 8, SIEV to secondary DIEP vena comitante reverse flow anastomosis.

Rohde and Keller<sup>14</sup> described a novel technique of venous augmentation where the SIEV was anastomosed to the proximal end of the other deep inferior epigastric vena comitantes to provide anterograde venous drainage. They reported 2 cases of salvage of congested DIEP flaps using this technique. Although our technique is similar, there is a critical technical difference. The end of the ligated SIEV is anastomosed to the distal end of one of the vena comitantes of the deep inferior epigastric system, resulting in reverse venous flow. The technique described by Rohde and Keller<sup>14</sup> maintained the natural flow through the other vena comitantes. This requires added dissection of the vena comitantes proximally within the flap. There is added morbidity to this dissection, which can potentially injure the deep inferior epigastric artery and/or other vena comitantes upstream (toward the flap) from the anastomoses to the internal mammary vessels. Injury to the vessels at this level could jeopardize the potential for flap salvage because the resulting injury would leave a very short pedicle for potential salvage.

We feel that our technique is simpler because the distal end of the vena comitantes is readily available and does not require the additional proximal end dissection and ligation that is required for the forward flow anastomosis. In addition to the time saved, our technique eliminates the potential trauma to the vascular pedicle to dissect the proximal end of the vena comitantes. The issue regarding the presence and direction of valves in the deep inferior epigastric system can be resolved by reviewing the anatomic study of the venous drainage of the transverse rectus abdominis musculocutaneous flap by Costa et al.<sup>15</sup> Despite the presence of valves throughout the deep inferior epigastric venous system, retrograde flow occurred easily. Several shunts exist between the vena comitantes of the deep inferior epigastric system at various locations

throughout their course. These shunts may explain the ability of our anastomosis to adapt to the reverse flow.

There are now increasing numbers of DIEP free flaps are used for autologous breast reconstruction. Use of our venous augmentation technique is a valuable tool for flap salvage. The SIEV is present in 95% of patients.<sup>16</sup> Routine preservation of the SIEV during DIEP flap harvest has proven to be very useful component, with minimal added time and morbidity. We have shown that use of the SIEV-DIEV reverse flow anastomosis is a simple and powerful method of venous augmentation for salvage of DIEP flap congestion.

## REFERENCES

1. Koshima I, Soeda S. Inferior epigastric artery skin flaps without rectus abdominis muscle. *Br J Plast Surg.* 1989;42:645–648.
2. Gill PS, Junt JP, Guerra AB, et al. A 10-year retrospective review of 758 DIEP flaps for breast reconstruction. *Plast Reconstr Surg.* 2004;113:1153–1160.
3. Kaplan JL, Allen RJ. Cost-based comparison between perforator flaps and TRAM flaps for breast reconstruction. *Plast Reconstr Surg.* 200;105:943–948.
4. Kroll SS, Sharma S, Koutz C, et al. Postoperative morphine requirements of free TRAM and DIEP flaps. *Plast Reconstr Surg.* 2001;107:338–341.
5. Futter CM, Webster MH, Hagen S, et al. A retrospective comparison of abdominal muscle strength following breast reconstruction with a free TRAM or DIEP flap. *Br J Plast Surg.* 2000;53:578–583.
6. Kroll SS. Fat necrosis in free transverse rectus abdominis myocutaneous and deep inferior epigastric perforator flaps. *Plast Reconstr Surg.* 2000;106:576–583.
7. Blondeel PN, Arnstein M, Verstraete K, et al. Venous congestion and blood flow in free transverse rectus abdominis myocutaneous and deep inferior epigastric perforator flaps. *Plast Reconstr Surg.* 2000;106:1295–1299.
8. Nahabedian MY, Tsangaris T, Momen B. Breast reconstruction with the DIEP flap or muscle-sparing (MS-2) free TRAM flap: is there a difference? *Plast Reconstr Surg.* 2005;115:445–446.

9. Wechselberger G, Schoeller T, Bauer T, et al. Venous superdrainage in deep inferior epigastric perforator flap breast reconstruction. *Plast Reconstr Surg*. 2001;108:162–166.
10. Villafane O, Gahankari D, Webster M. Superficial inferior epigastric vein (SIEV) “lifeboat” for DIEP/TRAM flaps. *Br J Plast Surg*. 1999;52:599.
11. Cohn AB, Walton RL. Immediate autologous breast reconstruction using muscle-sparing TRAM flaps with superficial epigastric system turbocharging: a salvage option. *J Reconstr Microsurg*. 2006;22:153–156.
12. Niranjana NS, Khandwala AR, Mackenzie DM. Venous augmentation of the free TRAM flap. *Br J Plast Surg*. 2001;54:335–337.
13. Tutor EG, Auba C, Benito A, et al. Easy venous superdrainage in DIEP flap breast reconstruction through the intercostals branch. *J Reconstr Microsurg*. 2002;18:595–598.
14. Rohde C, Keller A. Novel technique for venous augmentation in a free deep inferior epigastric perforator flap. *Ann Plast Surg*. 2005;55:528–530.
15. Costa MAC, Carriquiry C, Vasconez LO, et al. An anatomic study of the venous drainage of the transverse rectus abdominis musculocutaneous flap. *Plast Reconstr Surg*. 1987;79:208–213.
16. Reardon CM, Ceallaigh SO, O’Sullivan ST. An anatomical study of the superficial inferior epigastric vessels in humans. *Br J Plast Surg*. 2004;57:515–519.